



UGANDA

MEDICAL OUTREACH TRIP

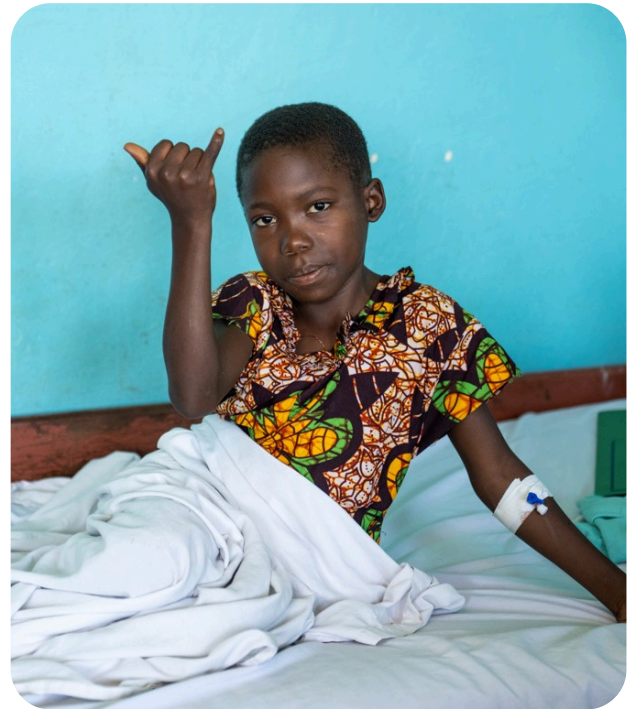Kampala, Uganda | Gulu, Uganda | Moyo, Uganda

Overview

Uganda has one of the lowest doctor-to-patient ratios in the world, with approximately one doctor for every 25,000 people. Ohana One, in collaboration with Pipeline Worldwide and local partners, conducted a transformative surgical outreach trip to Uganda, providing life-changing reconstructive procedures to patients who would have otherwise not had access to needed care. This outreach brought critical surgical care, medical training, and equipment donations.

With a dedicated team of 20 volunteers, the mission included 36 surgeries and 50 patient consultations, impacting individuals from infancy to adulthood. Beyond surgery, the team provided advanced medical training to hospital staff and introduced innovative technology to improve long-term patient care.

Complex procedures included burn contracture releases, keloid removals, and reconstructive hand surgeries



[View Outreach Trip Photos](#)



20 Ohana volunteers assisting on the trip

50 consultations with patients provided

36 surgeries performed on 38 patients

8 months - 36 years age range of patients

\$75,000+ of medical equipment donated



Surgical Team

UGANDA MEDICAL OUTREACH TRIP



Ohana One Team

David Kulber, MD
Kylie Tanabe, PA-C
Anne Marie Roust, MD
Carole Kulber
Sophie Skelton
Kelly Fogel
Zachary Greenwood
Sharon Oreck
Peter Ronoh

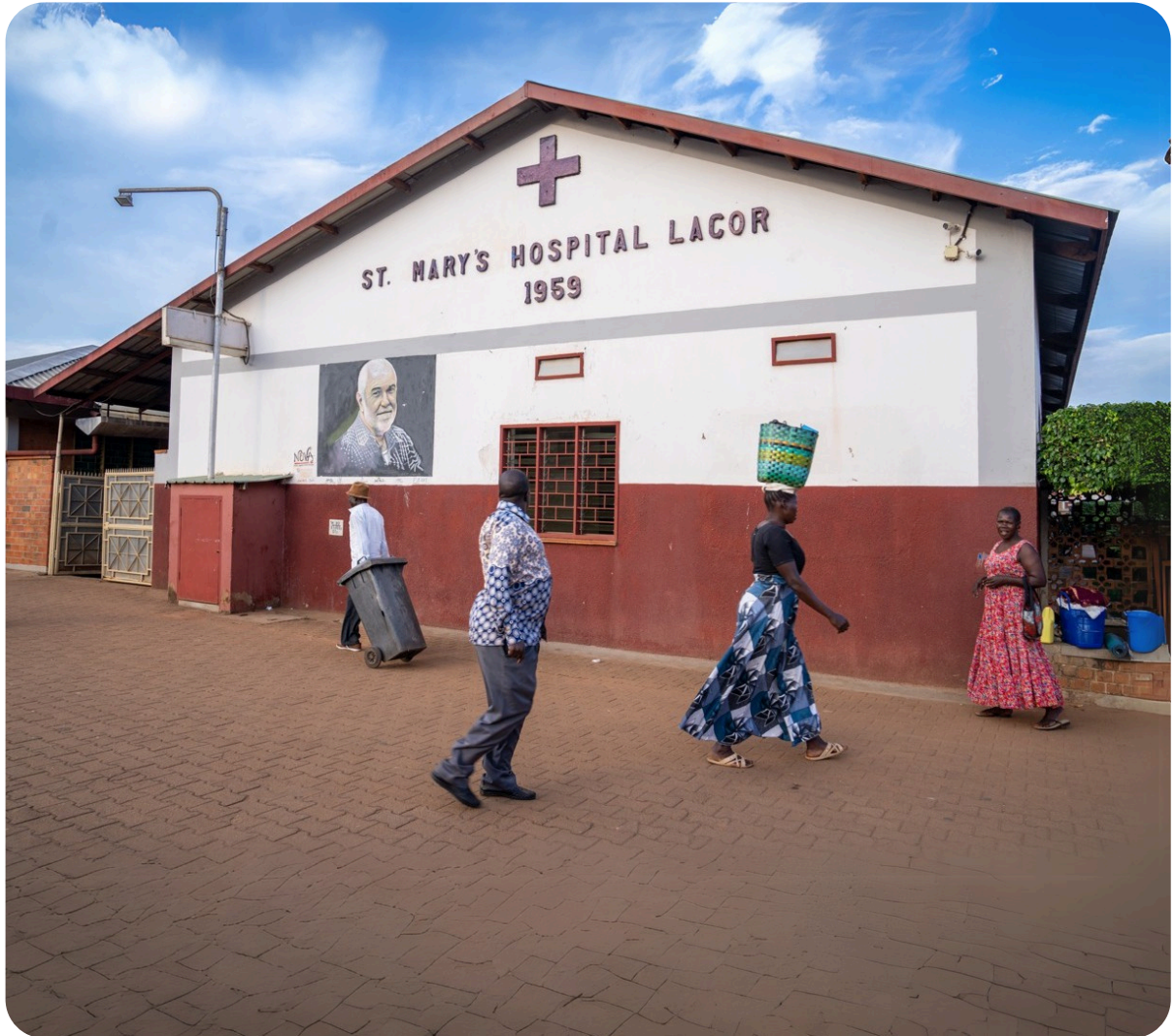Pipeline Worldwide

Dr. Jeff Smith
Dr. James Kaliri
Ishmael Hinson
Terence Crawford
leasha Person
Jessica McClellan
Kevin McClellan
Ken Kobs
Nathan Kobs
Jamie Nollette



PIPELINE
WORLDWIDE

Itinerary Highlights



Kampala

Meetings with vendors, the Infectious Disease Institute, and the U.S. Ambassador



Gulu

Hospital tour, patient rounds, surgical procedures, and the "Smile Again" party



Moyo

Community engagement, hospital visits, surgical procedures, and educational activities



Beyond Surgical Success

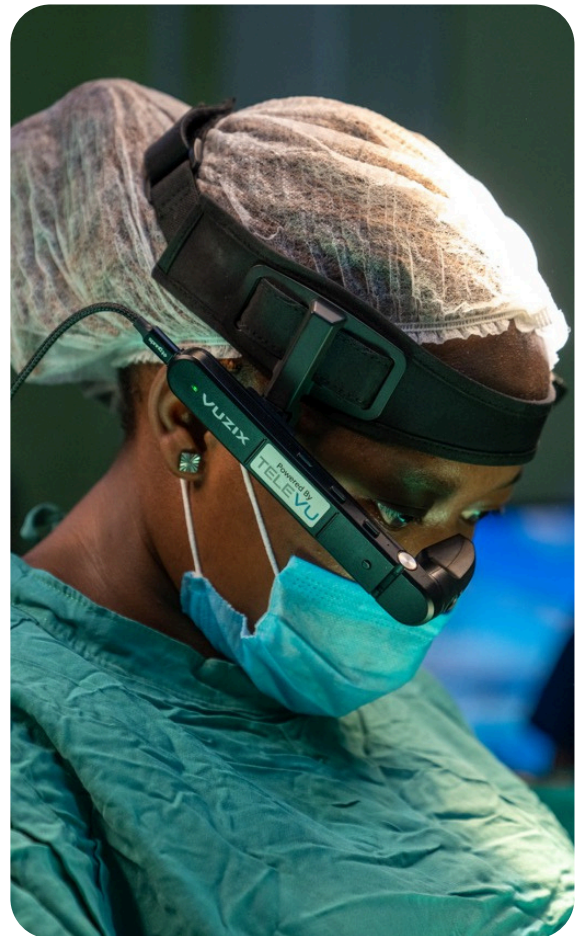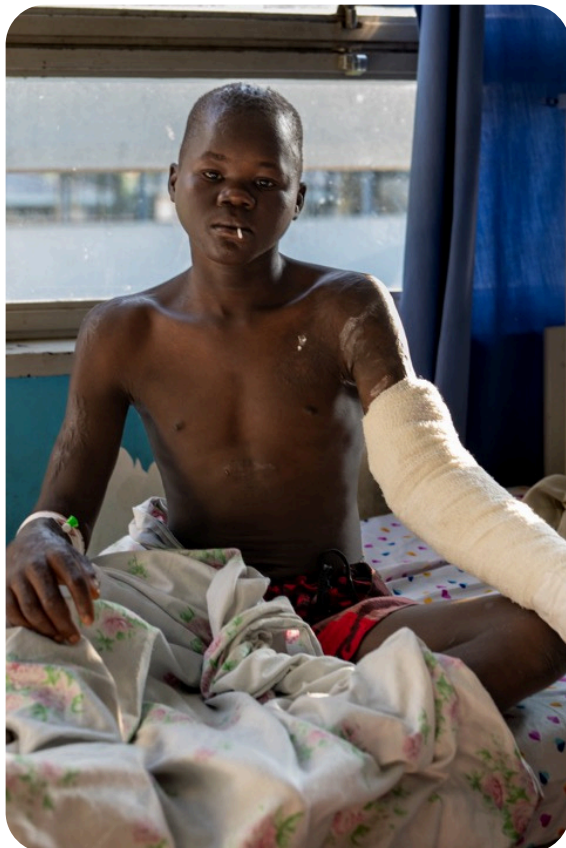Training & Innovation

The impact of Ohana One's Uganda Surgical Outreach extended beyond surgery, leaving a lasting mark on local medical care:

Training for hospital staff on **ultrasound and videolaryngoscope techniques** to enhance patient care.

Training on **surgical preparation** to ensure medications are easily accessible during procedures.

Repair of the long-defunct C-Arm X-ray machine at Lacor Hospital by Ohana One's Peter Ronoh, restoring a vital diagnostic tool.

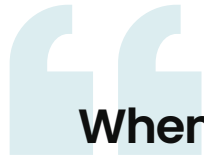

Training local surgeons on the use of **Smart Glasses**, allowing for continued learning and real-time consultations beyond the trip.

And, of course, Kiki the clown brought laughter and joy to patients and families, reinforcing that healing includes both medical treatment and emotional support.



Local Surgeon Testimonial



When I was asked to coordinate the Ohana One and Pipeline surgical camp, I had no idea how transformative the experience would be. From rallying colleagues and making radio announcements to registering patients, the anticipation built steadily. When the team arrived in Gulu, I was honored to welcome them and witness their warmth, kindness, and unwavering dedication to patient care.

Working alongside world-renowned experts like Dr. Smith, Dr. Kulber, and Kylie was an unforgettable privilege. Their meticulous approach and resilience in the operating room were truly inspiring. Beyond surgery, their empathy, humor, and tireless work left a lasting impact on both patients and staff. Ohana One and Pipeline International have bridged the gap for patients who would otherwise never receive these life-changing services. I hope for an even longer surgical camp in the future.



Dr. David Nyeko
St. Mary's Lacor Hospital



Patient Spotlight



Lola Acan

11 years old

Lola suffered severe burns to both hands at the age of one after falling into a fire during a community gathering. Her mother learned about the Ohana One surgical camp just days before their arrival and traveled for an entire day on a boda boda (a motorcycle taxi) with Lola and her younger sibling to reach the hospital.

Diagnosis: Severe burn contractures on both hands, limiting mobility.

Outcome: Underwent multiple surgeries, including contracture releases, grafts, and K-wire fixation, restoring movement and function in both hands.

Hospital: St. Mary's Hospital



Geoffrey Rwotomiym

9 years old

Geoffrey, a 9-year-old from Amuru District, developed compartment syndrome after his hand began to swell two years ago. His family traveled four hours by boda boda to reach the hospital and has been camping here for 14 days to receive treatment. His mother, who has six other children, learned about the plastics camp through an ad on Radio Mega, giving Geoffrey the chance for much-needed surgical care.

Diagnosis: Compartment syndrome causing swelling and restricted function in the hand.

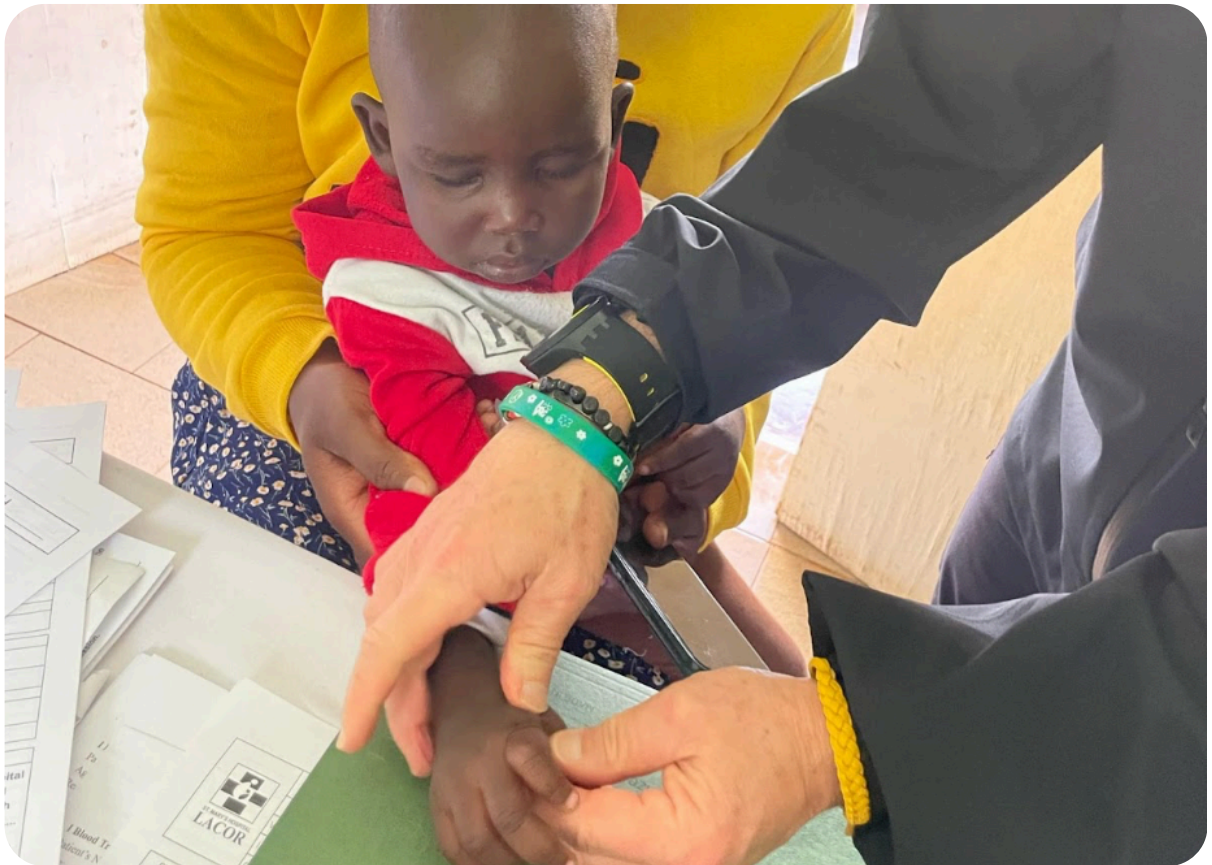Outcome: Successfully treated through surgery, improving hand function and reducing swelling.

Hospital: Moyo Hospital



Patient Spotlight

Elizabeth Kawa



At just eight months old, Elizabeth grabbed a hot motorcycle exhaust pipe, severely burning her left hand. Her mother, a teacher from Atiak, missed a similar surgical camp the previous year and was determined not to miss this opportunity. They traveled via boda boda and stayed at the hospital for two weeks, despite financial hardships.

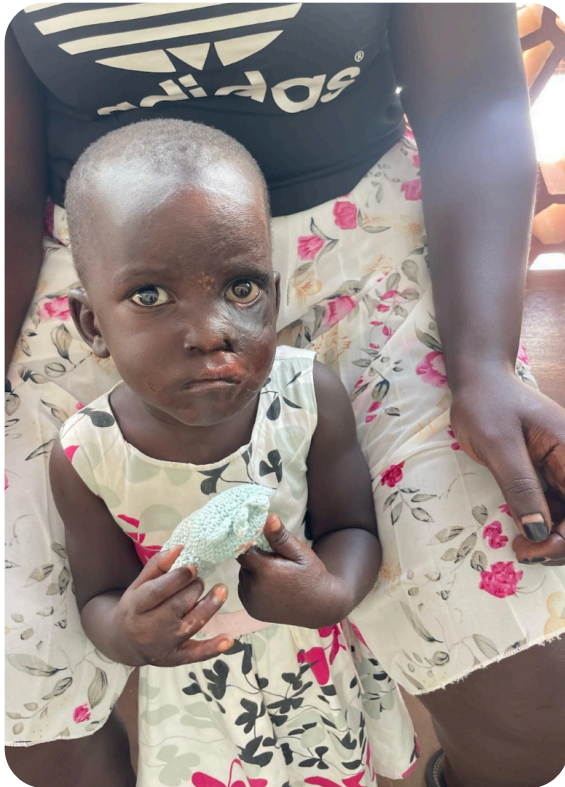Diagnosis: Burn contracture on the right hand, limiting dexterity.

Outcome: Underwent a right 2nd digit release, restoring hand function.

Hospital: St. Mary's Hospital



Patient Spotlight



Giffy Apio

22 months old

While learning to walk, Giffy fell onto burning charcoal, resulting in severe facial burns. Her mother, after hearing about the camp from a friend at the hospital, traveled three hours by boda boda and waited at the hospital for a week to ensure her daughter received care.

Diagnosis: Facial burn contractures affecting mobility.

Outcome: Underwent a facial contracture release, significantly improving movement and healing.

Hospital: St. Mary's Hospital



Patience Amaruot

9 years old

Patience, a 9-year-old from Gulu District, suffered burns after falling into a cooking fire two years ago. The injury caused contractures that limited movement in her right hand. She and her mother, who has two children, traveled one hour by boda boda to reach the hospital and have been staying away from home for 10 days to receive care. Her grandmother learned about the plastics camp through Radio Rupiny, leading to her opportunity for surgery.

Diagnosis: Right-hand contractures from burn injuries.

Outcome: Underwent a successful right two-digit release, improving mobility.

Hospital: St. Mary's Hospital



Patient Spotlight

Aromo Maurine



Maurine developed a keloid on her right ear after attempting to pierce it with a needle at age 15. Over time, the growth became more pronounced. Unlike many patients who had to camp at the hospital, she was able to travel back and forth from her village, Pece Acoyo, a 30-minute boda boda ride away. Her uncle received a call from the hospital through a connection about the plastics camp, giving her access to the care she needed.

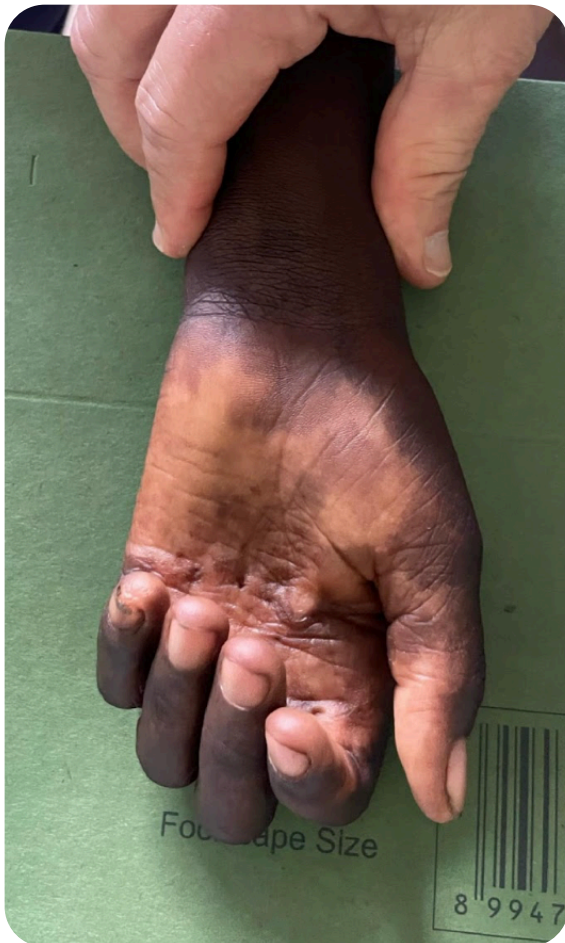Diagnosis: Right ear keloid from an infection after self-piercing.

Outcome: Underwent a successful keloid removal, restoring ear appearance.

Hospital: Moyo Hospital



Patient Spotlight



Okello Degracious


10 years old

Seven years ago, Degracious fell into a fire while playing near a communal evening fire, suffering burns to his left hand. His family heard about the surgical camp through a lucky radio announcement and immediately sought help.

Diagnosis: Burn contractures on the left hand, affecting movement.

Outcome: Received a left 4-digit release, restoring hand function and flexibility.

Hospital: St. Mary's Hospital



Oweka Junior

10 years old

Six years ago, Junior fell onto burning wood used for warmth, suffering a severe burn injury to his left wrist. His mother heard about the camp through Rupiny Radio, and they arrived five days before surgery.

Diagnosis: Severe left wrist contracture, limiting hand movement.

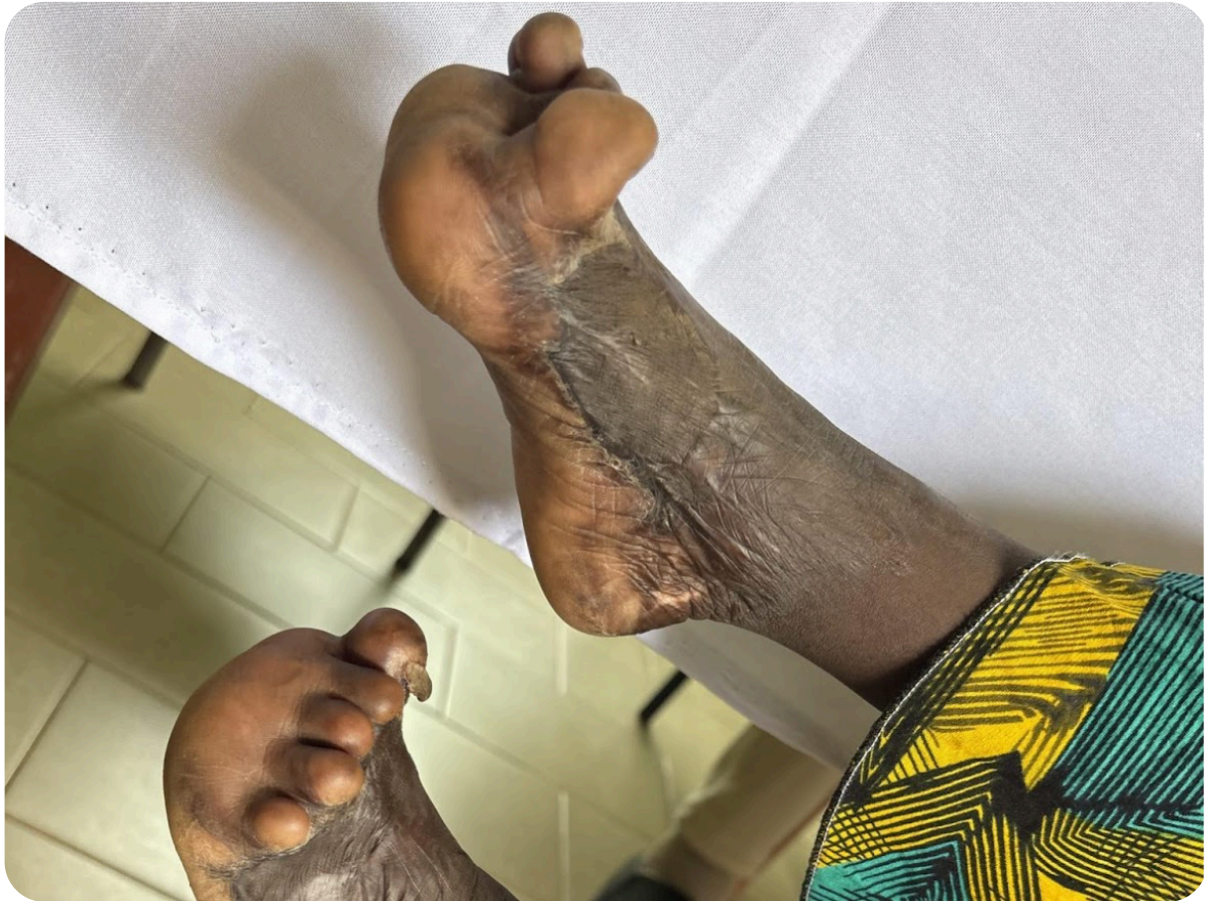Outcome: Received a left wrist contracture release, improving mobility and function.

Hospital: St. Mary's Hospital



Patient Spotlight

Christina Miyee



Christina, a 4-year-old from Layibi area, sustained burn injuries two years ago after stepping into an ash pile from a trash-burning site. Unlike many patients, she did not have to camp at the hospital, as her home was only a 15-minute boda boda ride away. She and her mother traveled back and forth for her appointments and surgery while her sibling remained at home. Her mother learned about the plastics camp after a friend who worked at the hospital saw the notice at St. Mary and sent it to her, ensuring Christina could receive care.

Diagnosis: Burn contracture from stepping into an ash pile.

Outcome: Successfully treated through surgery, improving function and healing.

Hospital: Moyo Hospital



Conclusion

The 2024 Uganda Surgical Outreach was a success, for the 36 patients who received life-changing surgeries, for the local healthcare teams who gained critical training and access to new medical technology, and for the more than \$75,000 in donated supplies. This trip reinforced the power of collaboration—between international experts, local surgeons, and community volunteers—to bring sustainable healthcare solutions to underserved regions.

We extend our deepest gratitude to our partners, donors, and volunteers who made this mission possible. The generosity of Americares, MAP International, and MTF Biologics. MTF Biologics donated over \$70,000 in medical supplies to this outreach trip fulfilling needs that can be met far beyond this trip.

Together, we are building a future where life-changing surgical care is accessible to all.



Photos except patient photos courtesy of Kelly Fogel Photography





PIPELINE™
WORLDWIDE



Learn more at ohanaone.one or scan the QR Code

Contact Jenny Davidson at jennydavidson@ohanaone.one
for more information.